

Laparoscopic Liver Resection

L.F. Abreu de Carvalho

Department of HPB Surgery & Liver Transplantation

Outline

- 1. Tools and concepts**
- 2. Standard liver resection?**
- 3. Surgery**
 1. Follow the veins
 2. Posterosuperior segments
 3. Hilar dissection
 4. Suturing
 5. Parenchymal transection
- 4. Conclusion**

Laparoscopic liver resection



- ▶ Haptic feedback
- ▶ > instruments & easier replacement
- ▶ Costs

- ▶ Camera
- ▶ Unwristed instruments
- ▶ Ergonomics
- ▶ Suturing

Laparoscopic liver resection



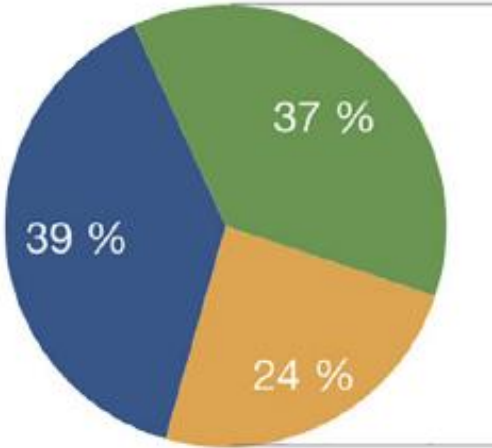
- ▶ Haptic feedback
- ▶ **> instruments & easier replacement**
- ▶ Costs

- ▶ Camera
- ▶ Unwristed instruments
- ▶ Ergonomics
- ▶ Suturing

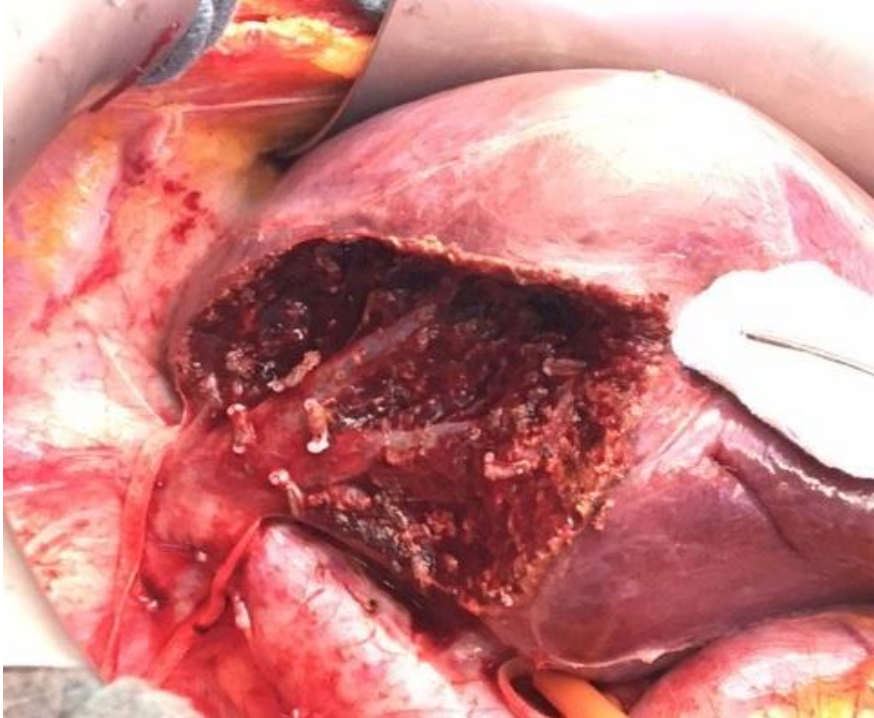

Standard liver resection?

● Yes, usually (for majority of cases) ● Yes, but occasionally (exceptional cases) ● Never

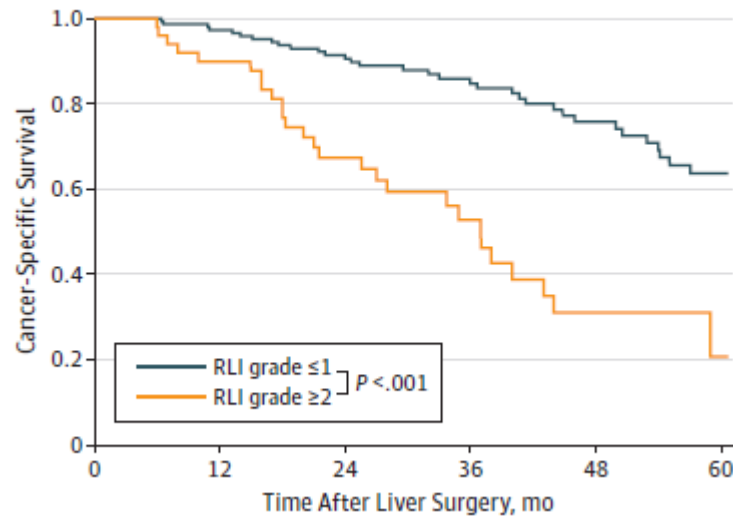


Exposure of hepatic veins during liver transection

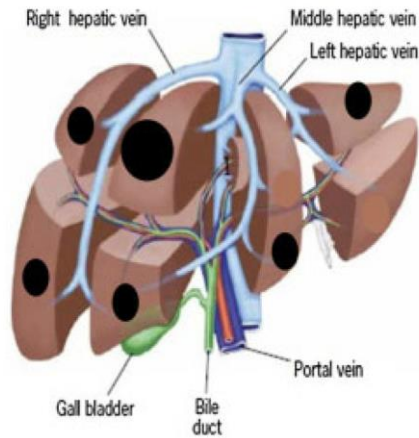
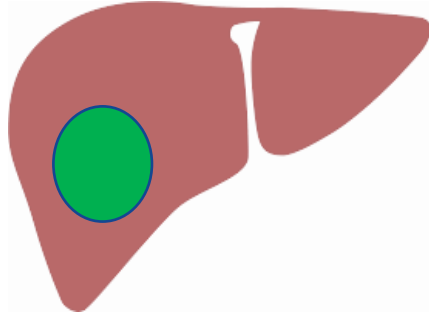
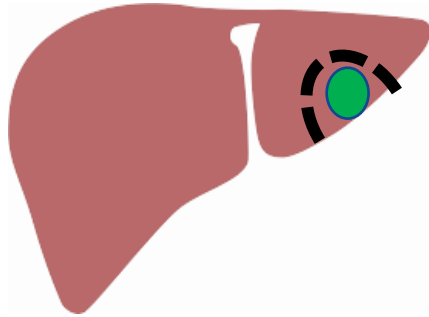


Remnant Liver Ischemia as a Prognostic Factor for Cancer-Specific Survival After Resection of Colorectal Liver Metastases

B Cancer-specific survival



CONCLUSIONS AND RELEVANCE In this study, remnant liver ischemia grade 2 or higher was associated with worse CSS after resection of CLMs. High-quality anatomic surgery to minimize RLI after resection is essential.



Control

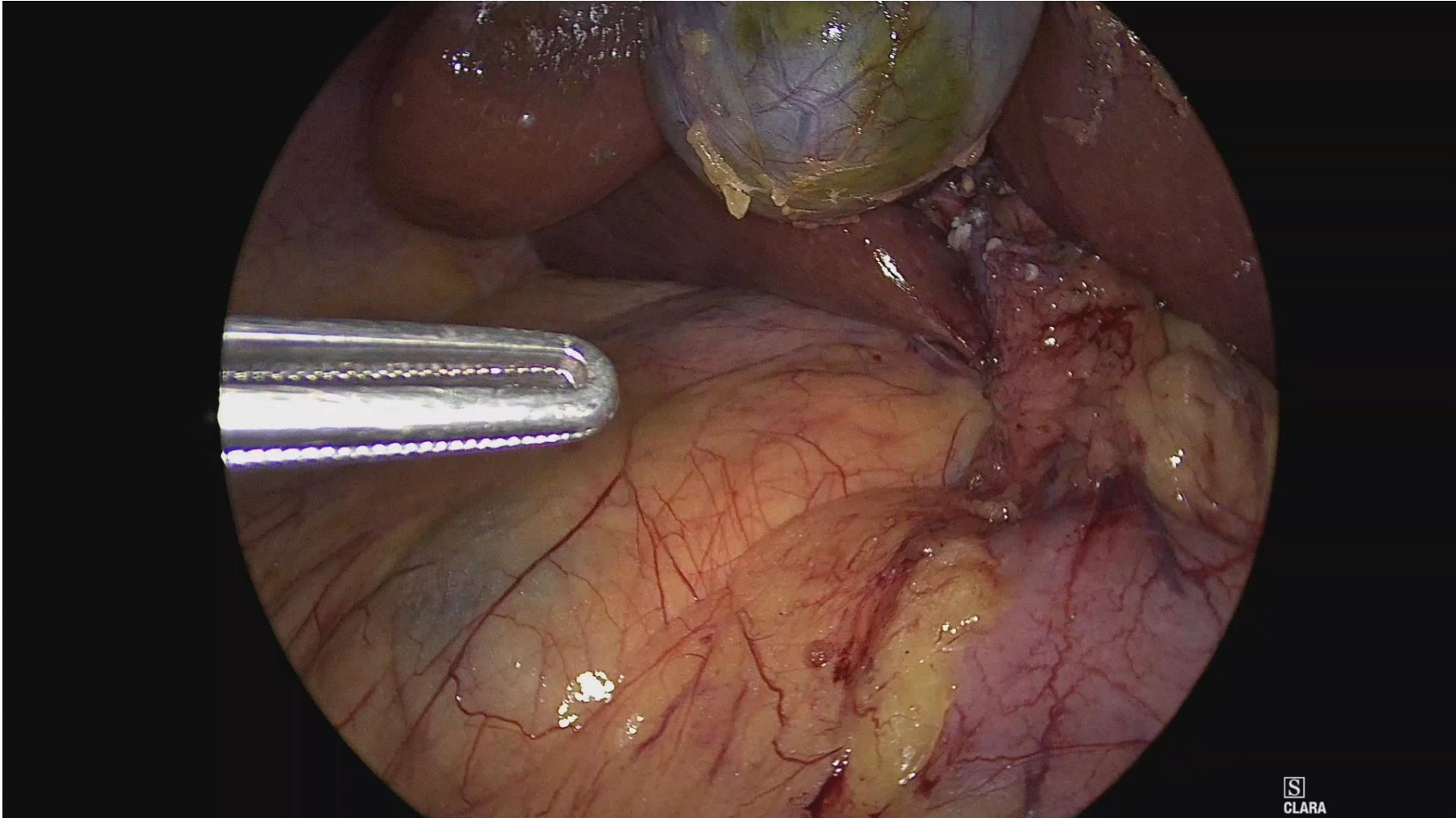
Precision

Performance

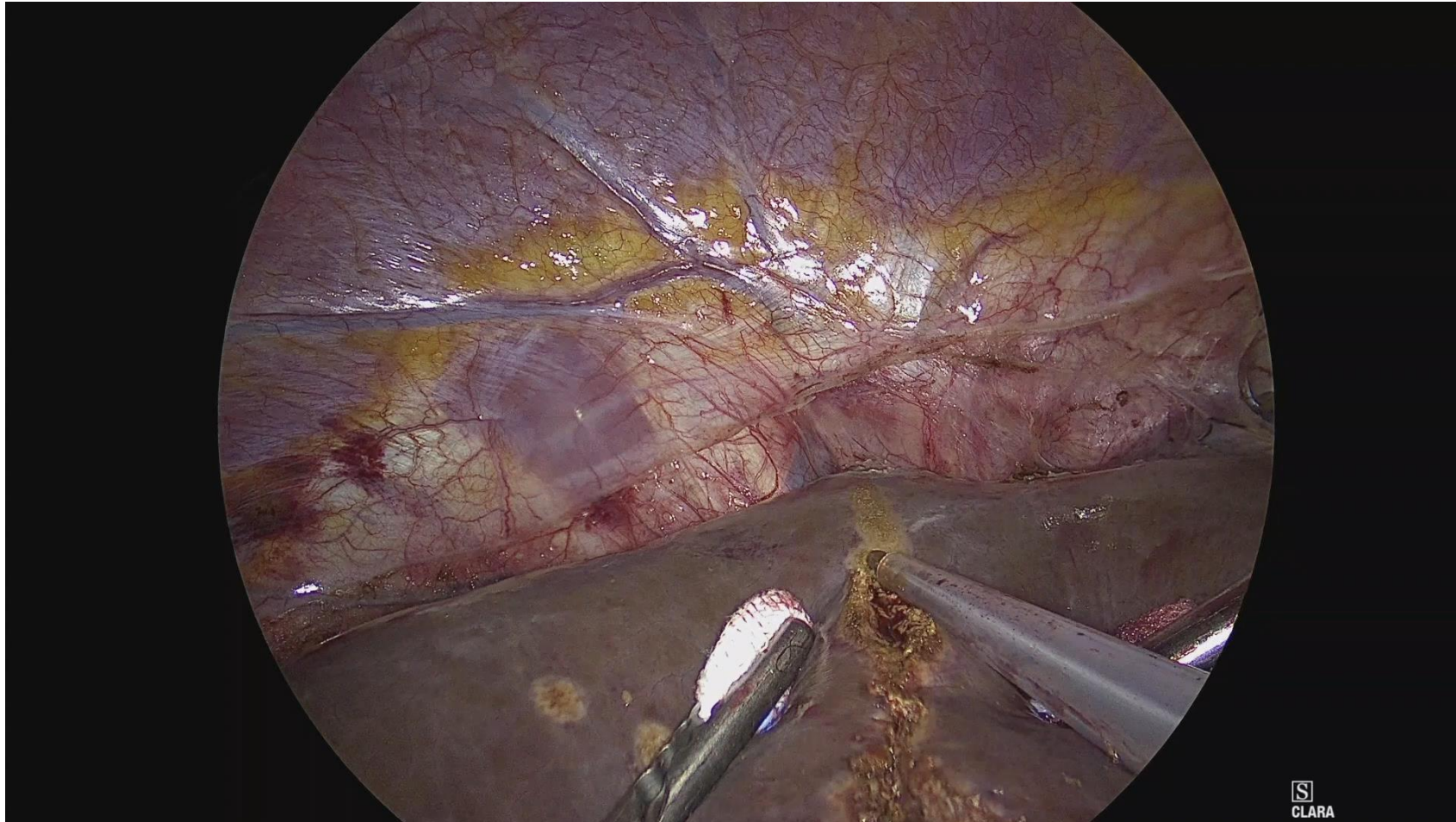
Speed

Innovation

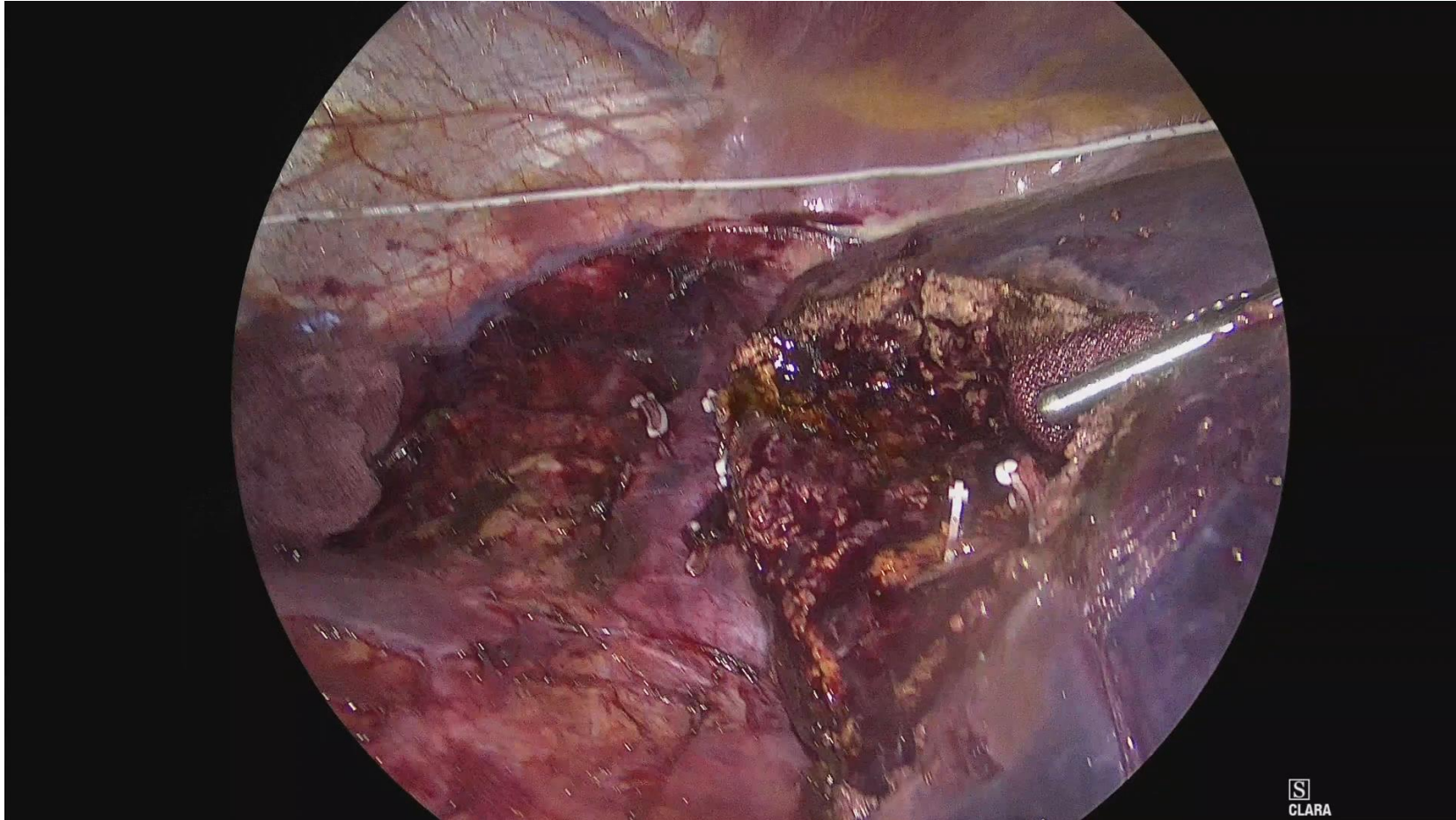
Posterosuperior segments



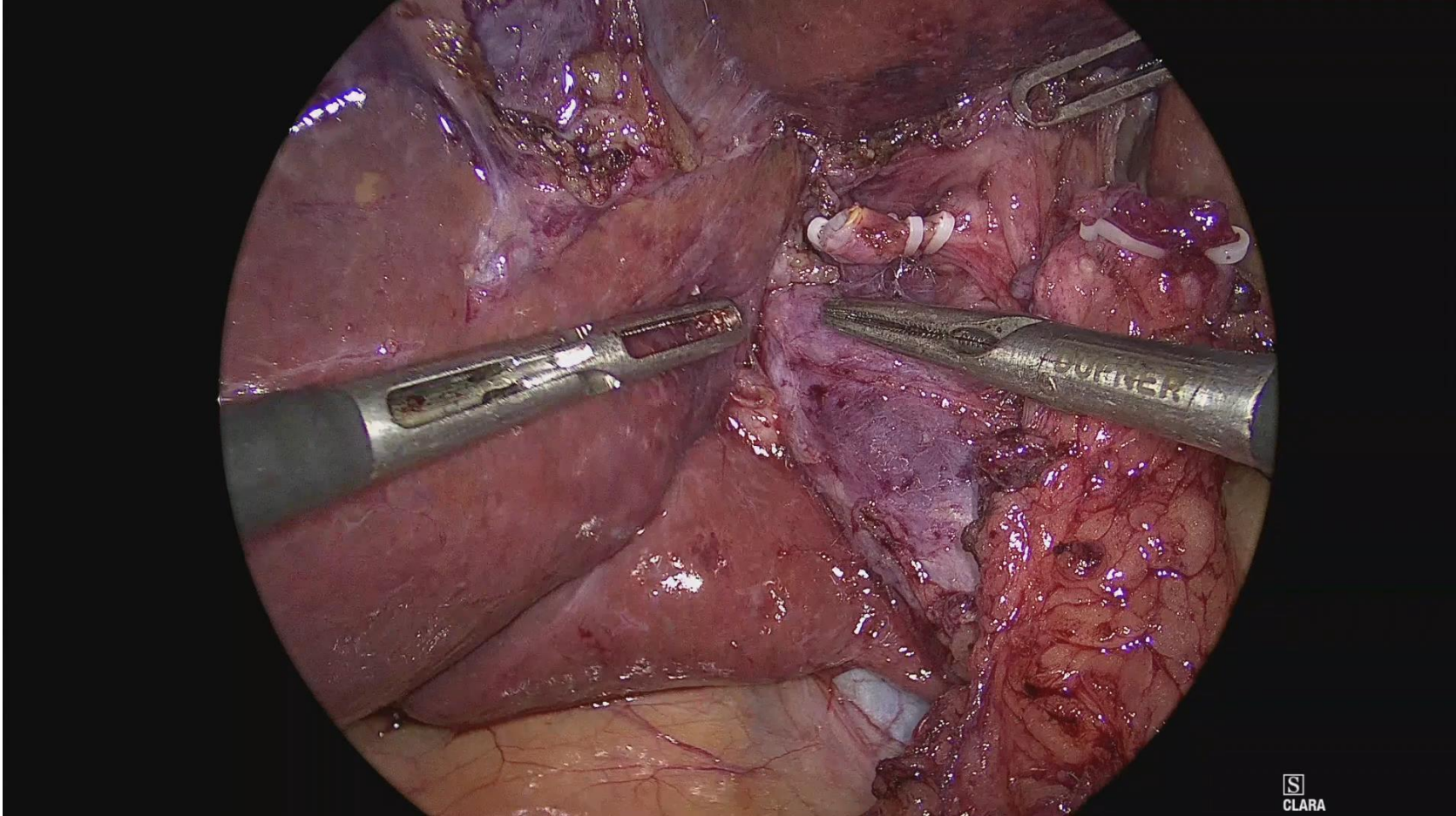
Follow the veins



Suturing



Hilar dissection



Parenchymal transection



